

ISSG Bibliography

2009-2017

Citations (N=163)

- 1) Bess S, Boachie-Adjei O, Burton D, Cunningham M, Shaffrey C, Shelokov A, et al. Pain and disability determine treatment modality for older patients with adult scoliosis, while deformity guides treatment for younger patients. *Spine (Phila Pa 1976)* 2009;34:2186–90. doi:10.1097/BRS.0b013e3181b05146.
- 2) Klineberg E, Schwab FJ, Ames CP, Hostin R, Bess S, Smith JS, et al. Acute reciprocal changes distant from the site of spinal osteotomies affect global postoperative alignment. *Adv Orthop* 2011;2011:415946. doi:10.4061/2011/415946.
- 3) Lafage V, Schwab FJ, Vira S, Hart R, Burton D, Smith JS, et al. Does vertebral level of pedicle subtraction osteotomy correlate with degree of spinopelvic parameter correction? *J Neurosurg Spine* 2011;14:184–91. doi:10.3171/2010.9.SPINE10129.
- 4) Ames CP, Smith JS, Scheer JK, Bess S, Bederman SS, Deviren V, et al. Impact of spinopelvic alignment on decision making in deformity surgery in adults: A review. *J Neurosurg Spine* 2012;16:547–64. doi:10.3171/2012.2.SPINE11320.
- 5) Hostin R, McCarthy I, O'Brien M, Bess S, Line B, Boachie-Adjei O, et al. Incidence, Mode, and Location of Acute Proximal Junctional Failures Following Surgical Treatment for Adult Spinal Deformity. *Spine (Phila Pa 1976)* 2012;38:1008–15. doi:10.1097/BRS.0b013e318271319c.
- 6) Lafage V, Ames C, Schwab FJ, Klineberg E, Akbarnia B, Smith J, et al. Changes in thoracic kyphosis negatively impact sagittal alignment after lumbar pedicle subtraction osteotomy: a comprehensive radiographic analysis. *Spine (Phila Pa 1976)* 2012;37:E180-7. doi:10.1097/BRS.0b013e318225b926.
- 7) Lafage V, Bharucha NJ, Schwab FJ, Hart R a, Burton D, Boachie-Adjei O, et al. Multicenter validation of a formula predicting postoperative spinopelvic alignment. *J Neurosurg Spine* 2012;16:15–21. doi:10.3171/2011.8.SPINE11272.
- 8) Lafage V, Smith JS, Bess S, Schwab FJ, Ames CP, Klineberg E, et al. Sagittal spino-pelvic alignment failures following three column thoracic osteotomy for adult spinal deformity. *Eur Spine J* 2012;21:698–704. doi:10.1007/s00586-011-1967-3.
- 9) Schwab FJ, Hawkinson N, Lafage V, Smith JS, Hart R, Mundis G, et al. Risk factors for major peri-operative complications in adult spinal deformity surgery: a multi-center review of 953 consecutive patients. *Eur Spine J* 2012;21:2603–10. doi:10.1007/s00586-012-2370-4.
- 10) Schwab FJ, Patel A, Shaffrey CI, Smith JS, Farcy J-P, Boachie-Adjei O, et al. Sagittal realignment failures following pedicle subtraction osteotomy surgery: are we doing enough? *J Neurosurg Spine* 2012;16:539–46. doi:10.3171/2012.2.SPINE11120.
- 11) Smith JS, Bess S, Shaffrey CI, Burton DC, Hart R a, Hostin R, et al. Dynamic changes of the pelvis and spine are key to predicting postoperative sagittal alignment after pedicle subtraction osteotomy: a critical analysis of preoperative planning techniques. *Spine (Phila Pa 1976)* 2012;37:845–53. doi:10.1097/BRS.0b013e31823b0892.
- 12) Smith JS, Shaffrey CI, Ames CP, Demakakos J, Fu K-MG, Keshavarzi S, et al. Assessment of symptomatic rod fracture after posterior instrumented fusion for adult spinal deformity. *Neurosurgery* 2012;71:862–7. doi:10.1227/NEU.0b013e3182672aab.
- 13) Smith JS, Shaffrey CI, Lafage V, Blondel B, Schwab FJ, Hostin R, et al. Spontaneous improvement of cervical alignment after correction of global sagittal balance following pedicle subtraction osteotomy. *J Neurosurg Spine* 2012;17:300–7. doi:10.3171/2012.6.SPINE1250.

- 14) Tang J a, Scheer JK, Smith JS, Deviren V, Bess S, Hart R a, et al. The impact of standing regional cervical sagittal alignment on outcomes in posterior cervical fusion surgery. *Neurosurgery* 2012;71:662–9; discussion 669. doi:10.1227/NEU.0b013e31826100c9.
- 15) Akbar M, Terran J, Ames CP, Lafage V, Schwab FJ. Use of Surgimap Spine in sagittal plane analysis, osteotomy planning, and correction calculation. *Neurosurg Clin N Am* 2013;24:163–72. doi:10.1016/j.nec.2012.12.007.
- 16) Ames CP, Smith JS, Scheer JK, Shaffrey CI, Lafage V, Deviren V, et al. A standardized nomenclature for cervical spine soft-tissue release and osteotomy for deformity correction: clinical article. *J Neurosurg Spine* 2013;19:269–78. doi:10.3171/2013.5.SPINE121067.
- 17) Bess S, Schwab FJ, Lafage V, Shaffrey CI, Ames CP. Classifications for adult spinal deformity and use of the Scoliosis Research Society-Schwab Adult Spinal Deformity Classification. *Neurosurg Clin N Am* 2013;24:185–93. doi:10.1016/j.nec.2012.12.008.
- 18) Iondel B, Schwab FJ, Bess S, Ames CP, Mummaneni P V, Hart R, et al. Posterior global malalignment after osteotomy for sagittal plane deformity: it happens and here is why. *Spine (Phila Pa 1976)* 2013;38:E394-401. doi:10.1097/BRS.0b013e3182872415.
- 19) Fu K-MG, Smith JS, Burton DC, Shaffrey CI, Boachie-Adjei O, Carlson B, et al. Outcomes and complications of extension of previous long fusion to the sacro-pelvis: is an anterior approach necessary? *World Neurosurg* 2013;79:177–81. doi:10.1016/j.wneu.2012.06.016.
- 20) Fu K-MG, Smith JS, Shaffrey CI, Ames CP, Bess S. Coronal realignment and reduction techniques and complication avoidance. *Neurosurg Clin N Am* 2013;24:195–202. doi:10.1016/j.nec.2012.12.011.
- 21) Gupta MC, Kebaish K, Blondel B, Klineberg E. Spinal osteotomies for rigid deformities. *Neurosurg Clin N Am* 2013;24:203–11. doi:10.1016/j.nec.2012.12.001.
- 22) Hart R a, Cabalo A, Bess S, Akbarnia B a, Boachie-Adjei O, Burton D, et al. Comparison of patient and surgeon perceptions of adverse events after adult spinal deformity surgery. *Spine (Phila Pa 1976)* 2013;38:732–6. doi:10.1097/BRS.0b013e31827ae242.
- 23) Hart R a, McCarthy I, Ames CP, Shaffrey CI, Hamilton DK, Hostin R. Proximal junctional kyphosis and proximal junctional failure. *Neurosurg Clin N Am* 2013;24:213–8. doi:10.1016/j.nec.2013.01.001.
- 24) Hart R, McCarthy I, O'Brien M, Bess S, Line B, Adjei OB, et al. Identification of Decision Criteria for Revision Surgery among Patients with Proximal Junctional Failure following Surgical Treatment for Spinal Deformity. *Spine (Phila Pa 1976)* 2013;38:1223–7. doi:10.1097/BRS.0b013e31829fedde.
- 25) Kasliwal MK, Smith JS, Kanter A, Chen C-J, Mummaneni P V, Hart R a, et al. Management of high-grade spondylolisthesis. *Neurosurg Clin N Am* 2013;24:275–91. doi:10.1016/j.nec.2012.12.002.
- 26) Klineberg E, Schwab FJ, Smith JS, Gupta MC, Lafage V, Bess S. Sagittal spinal pelvic alignment. *Neurosurg Clin N Am* 2013;24:157–62. doi:10.1016/j.nec.2012.12.003.
- 27) McCarthy IM, Hostin R a, O'Brien MF, Fleming NS, Ogola G, Kudyakov R, et al. Analysis of the direct cost of surgery for four diagnostic categories of adult spinal deformity. *Spine J* 2013;13:1843–8. doi:10.1016/j.spinee.2013.06.048.
- 28) McCarthy I, Hostin R, O'Brien M, Fleming N, Ogola G, Kudyakov R, et al. Cost-Effectiveness of Surgical Treatment for Adult Spinal Deformity: A Comparison of Dollars per Quality of Life Improvement Across Health Domains. *Spine Deform* 2013;1:293–8. doi:10.1016/j.jspd.2013.05.007.
- 29) McCarthy I, Hostin R, O'Brien M, Saigal R, Ames CP. Health economic analysis of adult deformity surgery. *Neurosurg Clin N Am* 2013;24:293–304. doi:10.1016/j.nec.2012.12.005.
- 30) Mummaneni P V, Tu T-H, Ziewacz JE, Akinbo OC, Deviren V, Mundis GM. The role of minimally invasive techniques in the treatment of adult spinal deformity. *Neurosurg Clin N Am*

- 2013;24:231–48. doi:10.1016/j.nec.2012.12.004.
- 31) Scheer JK, Ames CP, Deviren V. Assessment and treatment of cervical deformity. *Neurosurg Clin N Am* 2013;24:249–74. doi:10.1016/j.nec.2012.12.010.
 - 32) Scheer JK, Tang J a, Smith JS, Acosta FL, Protopsaltis TS, Blondel B, et al. Cervical spine alignment, sagittal deformity, and clinical implications. *J Neurosurg Spine* 2013;19:141–59. doi:10.3171/2013.4.SPINE12838.
 - 33) Scheer JK, Tang J a, Smith JS, Klineberg E, Hart R a, Mundis GM, et al. Reoperation rates and impact on outcome in a large, prospective, multicenter, adult spinal deformity database: clinical article. *J Neurosurg Spine* 2013;19:464–70. doi:10.3171/2013.7.SPINE12901.
 - 34) Schwab FJ, Blondel B, Bess S, Hostin R, Shaffrey CI, Smith JS, et al. Radiographical spinopelvic parameters and disability in the setting of adult spinal deformity: a prospective multicenter analysis. *Spine (Phila Pa 1976)* 2013;38:E803-12. doi:10.1097/BRS.0b013e318292b7b9.
 - 35) Smith JS, Klineberg E, Schwab FJ, Shaffrey CI, Moal B, Ames CP, et al. Change in classification grade by the SRS-Schwab Adult Spinal Deformity Classification predicts impact on health-related quality of life measures: prospective analysis of operative and nonoperative treatment. *Spine (Phila Pa 1976)* 2013;38:1663–71. doi:10.1097/BRS.0b013e31829ec563.
 - 36) Smith JS, Shaffrey CI, Fu K-MG, Scheer JK, Bess S, Lafage V, et al. Clinical and radiographic evaluation of the adult spinal deformity patient. *Neurosurg Clin N Am* 2013;24:143–56. doi:10.1016/j.nec.2012.12.009.
 - 37) Terran J, Schwab FJ, Shaffrey CI, Smith JS, Devos P, Ames CP, et al. The SRS-schwab adult spinal deformity classification: Assessment and clinical correlations based on a prospective operative and nonoperative cohort. *Neurosurgery* 2013;73:559–68. doi:10.1227/NEU.0000000000000012.
 - 38) Bess S, Line BG, Lafage V, Schwab FJ, Shaffrey CI, Hart R a, et al. Does recombinant human bone morphogenetic protein-2 use in adult spinal deformity increase complications and are complications associated with location of rhBMP-2 use? A prospective, multicenter study of 279 consecutive patients. *Spine (Phila Pa 1976)* 2014;39:233–42. doi:10.1097/BRS.0000000000000104.
 - 39) Bianco K, Norton R, Schwab FJ, Smith JS, Klineberg E, Obeid I, et al. Complications and intercenter variability of three-column osteotomies for spinal deformity surgery: a retrospective review of 423 patients. *Neurosurg Focus* 2014;36:E18. doi:10.3171/2014.2.FOCUS1422.
 - 40) Clark AJ, Garcia RM, Keefe MK, Koski TR, Rosner MK, Smith JS, et al. Results of the AANS membership survey of adult spinal deformity knowledge: impact of training, practice experience, and assessment of potential areas for improved education: Clinical article. *J Neurosurg Spine* 2014;21:640–7. doi:10.3171/2014.5.SPINE121146.
 - 41) Fu KMG, Smith JS, Burton DC, Kebaish KM, Shaffrey CI, Schwab FJ, et al. Revision Extension to the Pelvis versus Primary Spinopelvic Instrumentation in Adult Deformity: Comparison of Clinical Outcomes and Complications. *World Neurosurg* 2014. doi:10.1016/j.wneu.2013.02.059.
 - 42) Fu K-MG, Bess S, Shaffrey CI, Smith JS, Lafage V, Schwab FJ, et al. Patients with adult spinal deformity treated operatively report greater baseline pain and disability than patients treated nonoperatively; however, deformities differ between age groups. *Spine (Phila Pa 1976)* 2014;39:1401–7. doi:10.1097/BRS.0000000000000414.
 - 43) Haque RM, Mundis GM, Ahmed Y, El Ahmadieh TY, Wang MY, Mummaneni P V, et al. Comparison of radiographic results after minimally invasive, hybrid, and open surgery for adult spinal deformity: a multicenter study of 184 patients. *Neurosurg Focus* 2014;36:E13. doi:10.3171/2014.3.FOCUS1424.
 - 44) Kim HJ, Boachie-Adjei O, Shaffrey CI, Schwab FJ, Lafage V, Bess S, et al. Upper Thoracic versus Lower Thoracic Upper Instrumented Vertebrae Endpoints have Similar Outcomes and Complications in Adult Scoliosis. *Spine (Phila Pa 1976)* 2014;39:E795-9.

- doi:10.1097/BRS.0000000000000339.
- 45) Lafage V, Blondel B, Smith JS, Boachie-Adjei O, Hostin R a., Burton D, et al. Preoperative Planning for Pedicle Subtraction Osteotomy: Does Pelvic Tilt Matter? *Spine Deform* 2014;2:358–66. doi:10.1016/j.jspd.2014.05.006.
 - 46) Liu S, Schwab FJ, Smith JS, Klineberg E, Ames CP, Mundis G, et al. Likelihood of reaching minimal clinically important difference in adult spinal deformity: a comparison of operative and nonoperative treatment. *Ochsner J* 2014;14:67–77.
 - 47) Maier S, Smith JS, Schwab FJ, Obeid I, Mundis G, Klineberg E, et al. Revision Surgery After Three-Column Osteotomy in 335 Adult Spinal Deformity Patients: Inter-Center Variability and Risk Factors. *Spine (Phila Pa 1976)* 2014;39:881–5. doi:10.1097/BRS.0000000000000304.
 - 48) McCarthy IM, Hostin RA, Ames CP, Kim HJ, Smith JP, Boachie-Adjei O, et al. Total hospital costs of surgical treatment for adult spinal deformity: an extended follow-up study. *Spine J* 2014:1–7. doi:10.1016/j.spinee.2014.01.032.
 - 49) McCarthy I, O'Brien M, Ames C, Robinson C, Errico T, Polly DW, et al. Incremental cost-effectiveness of adult spinal deformity surgery: observed quality-adjusted life years with surgery compared with predicted quality-adjusted life years without surgery. *Neurosurg Focus* 2014;36:E3. doi:10.3171/2014.3.FOCUS1415.
 - 50) Moal B, Schwab FJ, Ames CP, Smith JS, Ryan D, Mummaneni P V, et al. Radiographic Outcomes of Adult Spinal Deformity Correction: A Critical Analysis of Variability and Failures Across Deformity Patterns. *Spine Deform* 2014;2:219–25. doi:10.1016/j.jspd.2014.01.003.
 - 51) Mummaneni P V, Shaffrey CI, Lenke LG, Park P, Wang MY, La Marca F, et al. The minimally invasive spinal deformity surgery algorithm: a reproducible rational framework for decision making in minimally invasive spinal deformity surgery. *Neurosurg Focus* 2014;36:E6. doi:10.3171/2014.3.FOCUS1413.
 - 52) Protosaltis T, Schwab FJ, Bronsard N, Smith JS, Klineberg E, Mundis G, et al. The T1 Pelvic Angle, a Novel Radiographic Measure of Global Sagittal Deformity, Accounts for Both Spinal Inclination and Pelvic Tilt and Correlates with Health-Related Quality of Life. *J Bone Jt Surg* 2014;96:1631–40. doi:10.2106/JBJS.M.01459.
 - 53) Ryan DJ, Protosaltis TS, Ames CP, Hostin R, Klineberg E, Mundis GM, et al. T1 Pelvic Angle (TPA) Effectively Evaluates Sagittal Deformity and Assesses Radiographical Surgical Outcomes Longitudinally. *Spine (Phila Pa 1976)* 2014;39:1203–10. doi:10.1097/BRS.0000000000000382.
 - 54) Scheer JK, Lafage V, Smith JS, Deviren V, Hostin R, McCarthy IM, et al. Maintenance of radiographic correction at 2 years following lumbar pedicle subtraction osteotomy is superior with upper thoracic compared with thoracolumbar junction upper instrumented vertebra. *Eur Spine J* 2014. doi:10.1007/s00586-014-3391-y.
 - 55) Scheer JK, Lafage V, Smith JS, Deviren V, Hostin R, McCarthy IM, et al. Impact of age on the likelihood of reaching a minimum clinically important difference in 374 three-column spinal osteotomies: clinical article. *J Neurosurg Spine* 2014;20:306–12. doi:10.3171/2013.12.SPINE13680.
 - 56) Slobodyanyuk K, Poorman CE, Smith JS, Protosaltis TS, Hostin R, Bess S, et al. Clinical improvement through nonoperative treatment of adult spinal deformity: who is likely to benefit? *Neurosurg Focus* 2014;36:E2. doi:10.3171/2014.3.FOCUS1426.
 - 57) Smith JS, Lafage V, Schwab FJ, Shaffrey CI, Protosaltis T, Klineberg E, et al. Prevalence and Type of Cervical Deformity Among 470 Adults With Throacolumbar Deformity. *Spine (Phila Pa 1976)* 2014;39:E1001-9. doi:10.1097/BRS.0000000000000432.
 - 58) Smith JS, Shaffrey E, Klineberg E, Shaffrey CI, Lafage V, Schwab FJ, et al. Prospective multicenter assessment of risk factors for rod fracture following surgery for adult spinal deformity. *J Neurosurg Spine* 2014;21:994–1003. doi:10.3171/2014.9.SPINE131176.

- 59) Smith JS, Singh M, Klineberg E, Shaffrey CI, Lafage V, Schwab FJ, et al. Surgical treatment of pathological loss of lumbar lordosis (flatback) in patients with normal sagittal vertical axis achieves similar clinical improvement as surgical treatment of elevated sagittal vertical axis. *J Neurosurg Spine* 2014;1–11. doi:10.3171/2014.3.SPINE13580.
- 60) Sparrey CJ, Bailey JF, Safaee M, Clark AJ, Lafage V, Schwab FJ, et al. Etiology of lumbar lordosis and its pathophysiology: a review of the evolution of lumbar lordosis, and the mechanics and biology of lumbar degeneration. *Neurosurg Focus* 2014;36:E1. doi:10.3171/2014.1.FOCUS13551.
- 61) Uribe JS, Deukmedjian AR, Mummaneni P V, Fu K-MG, Mundis GM, Okonkwo DO, et al. Complications in adult spinal deformity surgery: an analysis of minimally invasive, hybrid, and open surgical techniques. *Neurosurg Focus* 2014;36:E15. doi:10.3171/2014.3.FOCUS13534.
- 62) Wang MY, Mummaneni P V, Fu K-MG, Anand N, Okonkwo DO, Kanter AS, et al. Less invasive surgery for treating adult spinal deformities: ceiling effects for deformity correction with 3 different techniques. *Neurosurg Focus* 2014;36:E12. doi:10.3171/2014.3.FOCUS1423.
- 63) Ames CP, Smith JS, Eastlack R, Blaskiewicz DJ, Shaffrey CI, Schwab FJ, et al. Reliability assessment of a novel cervical spine deformity classification system. *J Neurosurg Spine* 2015;23:673–83. doi:10.3171/2014.12.SPINE14780.
- 64) Buckland AJ, Vigdorichik J, Schwab FJ, Errico TJ, Lafage R, Ames C, et al. Acetabular Anteversion Changes Due to Spinal Deformity Correction: Bridging the Gap Between Hip and Spine Surgeons. *J Bone Joint Surg Am* 2015;97:1913–20. doi:10.2106/JBJS.O.00276.
- 65) Daniels AH, Smith JS, Hiratzka J, Ames CP, Bess S, Shaffrey CI, et al. Functional Limitations Due to Lumbar Stiffness in Adults With and Without Spinal Deformity. *Spine (Phila Pa 1976)* 2015;40:1599–604. doi:10.1097/BRS.0000000000001090.
- 66) Fakurnejad S, Scheer JK, Lafage V, Smith JS, Deviren V, Hostin R, et al. The likelihood of reaching minimum clinically important difference and substantial clinical benefit at 2 years following a 3-column osteotomy: analysis of 140 patients. *J Neurosurg Spine* 2015;23:1–9. doi:10.3171/2014.12.SPINE141031.
- 67) Gupta, Munish C. MD*; Ferrero, Emmanuelle MD†; Mundis, Gregory MD‡; Smith, Justin S. MD, PhD§; Shaffrey, Christopher I. MD§; Schwab, Frank MD†; Kim, Han Jo MD¶; Boachie-Adjei, Oheneba MD¶; Lafage, Virginie PhD†; Bess, Shay MD||; Hostin, Richard MD**; Burt EMISSG. Pedicle Subtraction Osteotomy in the Revision Versus Primary Adult Spinal Deformity Patient: Is There a Difference in Correction and Complications? *Spine (Phila Pa 1976)* 2015;40:E1169–75. doi:10.1097/BRS.0000000000001107.
- 68) Klineberg E, Passias PG, Jalai CM, Worley N, Sciubba DM, Burton DC, et al. Predicting Extended Length of Hospital Stay in an Adult Spinal Deformity Surgical Population. *Spine (Phila Pa 1976)* 2015. doi:10.1097/BRS.0000000000001391.
- 69) Liu S, Lafage R, Smith JS, Protosaltis TS, Lafage V, Challier V, et al. Impact of dynamic alignment, motion, and center of rotation on myelopathy grade and regional disability in cervical spondylotic myelopathy. *J Neurosurg Spine* 2015;23:690–700. doi:10.3171/2015.2.SPINE14414.
- 70) Liu S, Tetreault L, Fehlings MG, Challier V, Smith JS, Shaffrey CI, et al. Novel Method Using Baseline Normalization and Area Under the Curve to Evaluate Differences in Outcome Between Treatment Groups and Application to Patients With Cervical Spondylotic Myelopathy Undergoing Anterior Versus Posterior Surgery. *Spine (Phila Pa 1976)* 2015;40:E1299–304. doi:10.1097/BRS.0000000000001152.
- 71) Maggio D, Ailon TT, Smith JS, Shaffrey CI, Lafage V, Schwab F, et al. Assessment of impact of standing long-cassette radiographs on surgical planning for lumbar pathology: an international survey of spine surgeons. *J Neurosurg Spine* 2015;23:581–8. doi:10.3171/2015.1.SPINE14833.
- 72) Moal B, Lafage V, Smith JS, Ames CP, Mundis G, Terran JS, et al. Clinical Improvement Through Surgery for Adult Spinal Deformity: What Can Be Expected and Who Is Likely to Benefit Most?

- Spine Deform 2015;3:566–74. doi:10.1016/j.jspd.2015.04.004.
- 73) Oh T, Scheer JK, Eastlack R, Smith JS, Lafage V, Protopsaltis TS, et al. Cervical compensatory alignment changes following correction of adult thoracic deformity: a multicenter experience in 57 patients with a 2-year follow-up. *J Neurosurg Spine* 2015;1–8. doi:10.3171/2014.10.SPINE14829.
- 74) Park P, Wang MY, Lafage V, Nguyen S, Ziewacz J, Okonkwo DO, et al. Comparison of two minimally invasive surgery strategies to treat adult spinal deformity. *J Neurosurg Spine* 2015;22:374–80. doi:10.3171/2014.9.SPINE131004.
- 75) Park P, Wang MY, Nguyen S, Mundis GM, La Marca F, Uribe JS, et al. Comparison of Complications and Clinical and Radiographic Outcomes Between Non-Obese and Obese Patients With Adult Spinal Deformity Undergoing Minimally Invasive Surgery. *World Neurosurg* 2015;87:55–60. doi:10.1016/j.wneu.2015.12.024.
- 76) [76] Passias PG, Soroceanu A, Smith J, Boniello A, Yang S, Scheer JK, et al. Postoperative cervical deformity in 215 thoracolumbar patients with adult spinal deformity: prevalence, risk factors, and impact on patient-reported outcome and satisfaction at 2-year follow-up. *Spine (Phila Pa 1976)* 2015;40:283–91. doi:10.1097/BRS.0000000000000746.
- 77) Passias PG, Soroceanu A, Scheer J, Yang S, Boniello A, Smith JS, et al. Magnitude of preoperative cervical lordotic compensation and C2-T3 angle are correlated to increased risk of postoperative sagittal spinal pelvic malalignment in adult thoracolumbar deformity patients at 2-year follow-up. *Spine J* 2015;15:1756–63. doi:10.1016/j.spinee.2015.04.007.
- 78) Protopsaltis TS, Scheer JK, Terran JS, Smith JS, Hamilton DK, Kim HJ, et al. How the neck affects the back: changes in regional cervical sagittal alignment correlate to HRQOL improvement in adult thoracolumbar deformity patients at 2-year follow-up. *J Neurosurg Spine* 2015;23:153–8. doi:10.3171/2014.11.SPINE1441.
- 79) Saigal R, Clark AJ, Scheer JK, Smith JS, Bess S, Mummaneni P V, et al. Adult Spinal Deformity Patients Recall Fewer Than 50% of the Risks Discussed in the Informed Consent Process Preoperatively and the Recall Rate Worsens Significantly in the Postoperative Period. *Spine (Phila Pa 1976)* 2015;40:1079–85. doi:10.1097/BRS.0000000000000964.
- 80) Scheer JK, Mundis GM, Klineberg E, Hart R a., Deviren V, Nguyen S, et al. Postoperative Recovery After Adult Spinal Deformity Surgery. *Spine (Phila Pa 1976)* 2015;40:1505–15. doi:10.1097/BRS.0000000000001062.
- 81) Scheer JK, Passias PG, Soroceanu AM, Boniello AJ, Mundis GM, Klineberg E, et al. Association between preoperative cervical sagittal deformity and inferior outcomes at 2-year follow-up in patients with adult thoracolumbar deformity: analysis of 182 patients. *J Neurosurg Spine* 2015;24:1–8. doi:10.3171/2015.3.SPINE141098.
- 82) Scheer JK, Smith JS, Clark AJ, Lafage V, Kim HJ, Rolston JD, et al. Comprehensive study of back and leg pain improvements after adult spinal deformity surgery: analysis of 421 patients with 2-year follow-up and of the impact of the surgery on treatment satisfaction. *J Neurosurg Spine* 2015;22:540–53. doi:10.3171/2014.10.SPINE14475.
- 83) Scheer JK, Mundis GM, Klineberg E, Hart RA, Deviren V, Burton DC, et al. Recovery following adult spinal deformity surgery: the effect of complications and reoperation in 149 patients with 2-year follow-up. *Eur Spine J* 2015. doi:10.1007/s00586-015-3787-3.
- 84) Sciubba DM, Yurter A, Smith JS, Kelly MP, Scheer JK, Goodwin CR, et al. A Comprehensive Review of Complication Rates After Surgery for Adult Deformity: A Reference for Informed Consent. *Spine Deform* 2015;3:575–94. doi:10.1016/j.jspd.2015.04.005.
- 85) Sciubba DM, Scheer JK, Smith JS, Lafage V, Klineberg E, Gupta M, et al. Which Daily Functions Are Most Affected by Stiffness Following Total Lumbar Fusion: Comparison of Upper Thoracic and Thoracolumbar Proximal Endpoints. *Spine (Phila Pa 1976)* 2015.

- doi:10.1097/BRS.0000000000000968.
- 86) Sciubba DM, Scheer JK, Yurter A, Smith JS, Lafage V, Klineberg E, et al. Patients with spinal deformity over the age of 75: a retrospective analysis of operative versus non-operative management. *Eur Spine J* 2015. doi:10.1007/s00586-015-3759-7.
 - 87) Smith JS, Shaffrey CI, Lafage V, Schwab FJ, Scheer JK, Protopsaltis T, et al. Comparison of best versus worst clinical outcomes for adult spinal deformity surgery: a retrospective review of a prospectively collected, multicenter database with 2-year follow-up. *J Neurosurg Spine* 2015;23:349–59. doi:10.3171/2014.12.SPINE14777.
 - 88) Soroceanu A, Burton DC, Diebo BG, Smith JS, Hostin R, Shaffrey CI, et al. Impact of obesity on complications, infection, and patient-reported outcomes in adult spinal deformity surgery. *J Neurosurg Spine* 2015;23:1–9. doi:10.3171/2015.3.SPINE14743.
 - 89) Soroceanu A, Diebo BG, Burton D, Smith JS, Deviren V, Shaffrey C, et al. Radiographical and Implant-Related Complications in Adult Spinal Deformity Surgery: Incidence, Patient Risk Factors, and Impact on Health-Related Quality of Life. *Spine (Phila Pa 1976)* 2015;40:1414–21. doi:10.1097/BRS.0000000000001020.
 - 90) Ailon T, Scheer JK, Lafage V, Schwab FJ, Klineberg E, Sciubba DM, et al. Adult Spinal Deformity Surgeons Are Unable to Accurately Predict Postoperative Spinal Alignment Using Clinical Judgment Alone. *Spine Deform* 2016;4:323–9. doi:10.1016/j.jspd.2016.02.003.
 - 91) Ames C, Gammal I, Matsumoto M, Hosogane N, Smith JS, Protopsaltis T, et al. Geographic and Ethnic Variations in Radiographic Disability Thresholds: Analysis of North American and Japanese Operative Adult Spinal Deformity Populations. *Neurosurgery* 2016;78:793–801. doi:10.1227/NEU.0000000000001184.
 - 92) Anand N, Cohen RB, Cohen J, Than K, Fessler RG, Nunley P, et al. Comparison of Early and Late Complications after Circumferential Minimally Invasive and Hybrid Surgery for Adult Spinal Deformity. *Ann Orthop Rheumatol* 2016;4:2–7.
 - 93) Bess S, Line B, Fu K-M, McCarthy I, Lafage V, Schwab FJ, et al. The Health Impact of Symptomatic Adult Spinal Deformity: Comparison of Deformity Types to United States Population Norms and Chronic Diseases. *Spine (Phila Pa 1976)* 2016;41:224–33. doi:10.1097/BRS.0000000000001202.
 - 94) Bess S, Protopsaltis TS, Lafage V, Lafage R, Ames CP, Errico T, et al. Clinical and Radiographic Evaluation of Adult Spinal Deformity. *Clin Spine Surg* 2016;29:6–16. doi:10.1097/BSD.0000000000000352.
 - 95) Daniels AH, Koller H, Hiratzka SL, Mayer M, Meier O, Contag AG, et al. Selecting caudal fusion levels: 2 year functional and stiffness outcomes with matched pairs analysis in multilevel fusion to L5 versus S1. *Eur Spine J* 2016. doi:10.1007/s00586-016-4790-z.
 - 96) Diebo BG, Lafage R, Ames CP, Bess S, Obeid I, Klineberg E, et al. Ratio of lumbar 3-column osteotomy closure: patient-specific deformity characteristics and level of resection impact correction of truncal versus pelvic compensation. *Eur Spine J* 2016. doi:10.1007/s00586-016-4533-1.
 - 97) Ferrero E, Vira S, Ames CP, Kebaish K, Obeid I, O'Brien MF, et al. Analysis of an unexplored group of sagittal deformity patients: low pelvic tilt despite positive sagittal malalignment. *Eur Spine J* 2016;25:3568–76. doi:10.1007/s00586-015-4048-1.
 - 98) Gupta M, Henry JK, Schwab FJ, Klineberg E, Smith JS, Gum J, et al. Dedicated Spine Measurement Software Quantifies Key Spino-Pelvic Parameters More Reliably Than Traditional Picture Archiving and Communication Systems Tools. *Spine (Phila Pa 1976)* 2016;41:E22-7. doi:10.1097/BRS.0000000000001216.
 - 99) Hamilton DK, Kanter AS, Bolinger BD, Mundis GM, Nguyen S, Mummaneni P V., et al. Reoperation rates in minimally invasive, hybrid and open surgical treatment for adult spinal deformity with minimum 2-year follow-up. *Eur Spine J* 2016;25:2605–11. doi:10.1007/s00586-

- 016-4443-2.
- 100) Harris BY, Roth MF, Diebo BG, Bess S, Theologis AA, Scheer JK, et al. Investigating the Universality of Preoperative Health-Related Quality of Life (HRQoL) for Surgically Treated Spinal Deformity in Young Adults: A Propensity Score-Matched Comparison Between African and US Populations. *Spine Deform* 2016;4:351–7. doi:10.1016/j.jspd.2016.03.006.
 - 101) Hart RA, Hiratzka J, Kane MS, Lafage V, Klineberg E, Ames CP, et al. Stiffness after Pan-Lumbar Arthrodesis for Adult Spinal Deformity Does Not Significantly Impact Patient Functional Status or Satisfaction Irrespective of Proximal Endpoint. *Spine (Phila Pa 1976)* 2016. doi:10.1097/BRS.0000000000002006.
 - 102) Hostin R, O'Brien M, McCarthy I, Bess S, Gupta M, Klineberg E, et al. Retrospective Study of Anterior Interbody Fusion Rates and Patient Outcomes of Using Mineralized Collagen and Bone Marrow Aspirate in Multilevel Adult Spinal Deformity Surgery. *Clin Spine Surg* 2016;29:E384-8. doi:10.1097/BSD.0b013e318292468f.
 - 103) Hostin R, Robinson C, O'Brien M, Ames C, Schwab FJ, Smith JS, et al. A Multicenter Comparison of Inpatient Resource Use for Adult Spinal Deformity Surgery. *Spine (Phila Pa 1976)* 2016;41:603–9. doi:10.1097/BRS.0000000000001280.
 - 104) Jain A, Lafage V, Kelly MP, Hassanzadeh H, Neuman BJ, Sciubba DM, et al. Validity, Reliability, and Responsiveness of SRS-7 as an Outcomes Assessment Instrument for Operatively Treated Patients with Adult Spinal Deformity. *Spine (Phila Pa 1976)* 2016:1–10. doi:10.1097/BRS.0000000000001540.
 - 105) Jalai CM, Passias PG, Lafage V, Smith JS, Lafage R, Poorman GW, et al. A comparative analysis of the prevalence and characteristics of cervical malalignment in adults presenting with thoracolumbar spine deformity based on variations in treatment approach over 2 years. *Eur Spine J* 2016;25:2423–32. doi:10.1007/s00586-016-4564-7.
 - 106) Kelly MP, Zebala LP, Kim HJ, Sciubba DM, Smith JS, Shaffrey CI, et al. Effectiveness of preoperative autologous blood donation for protection against allogeneic blood exposure in adult spinal deformity surgeries: a propensity-matched cohort analysis. *J Neurosurg Spine* 2016;24:124–30. doi:10.3171/2015.4.SPINE141329.
 - 107) Lafage R, Schwab FJ, Challier V, Henry JK, Gum J, Smith J, et al. Defining Spino-Pelvic Alignment Thresholds: Should Operative Goals in Adult Spinal Deformity Surgery Account for Age? *Spine (Phila Pa 1976)* 2016;41:62–8. doi:10.1097/BRS.0000000000001171.
 - 108) Lau D, Funao H, Clark AJ, Nicholls F, Smith J, Bess S, et al. The Clinical Correlation of the Hart-ISSG Proximal Junctional Kyphosis Severity Scale With Health-Related Quality-of-life Outcomes and Need for Revision Surgery. *Spine (Phila Pa 1976)* 2016;41:213–23. doi:10.1097/BRS.0000000000001326.
 - 109) Liu S, Diebo BG, Henry JK, Smith JS, Hostin R, Cunningham ME, et al. The benefit of nonoperative treatment for adult spinal deformity: identifying predictors for reaching a minimal clinically important difference. *Spine J* 2016;16:210–8. doi:10.1016/j.spinee.2015.10.043.
 - 110) Mummaneni P V, Park P, Fu K-M, Wang MY, Nguyen S, Lafage V, et al. Does Minimally Invasive Percutaneous Posterior Instrumentation Reduce Risk of Proximal Junctional Kyphosis in Adult Spinal Deformity Surgery? A Propensity-Matched Cohort Analysis. *Neurosurgery* 2016;78:101–8. doi:10.1227/NEU.0000000000001002.
 - 111) Park P, Okonkwo DO, Nguyen S, Mundis GM, Than KD, Deviren V, et al. Can a Minimal Clinically Important Difference Be Achieved in Elderly Patients with Adult Spinal Deformity Who Undergo Minimally Invasive Spinal Surgery? *World Neurosurg* 2016;86:168–72. doi:10.1016/j.wneu.2015.09.072.
 - 112) Passias PG, Klineberg E, Jalai CM, Worley N, Poorman GW, Line B, et al. Hospital Readmission within Two Years Following Adult Thoracolumbar Spinal Deformity Surgery: Prevalence,

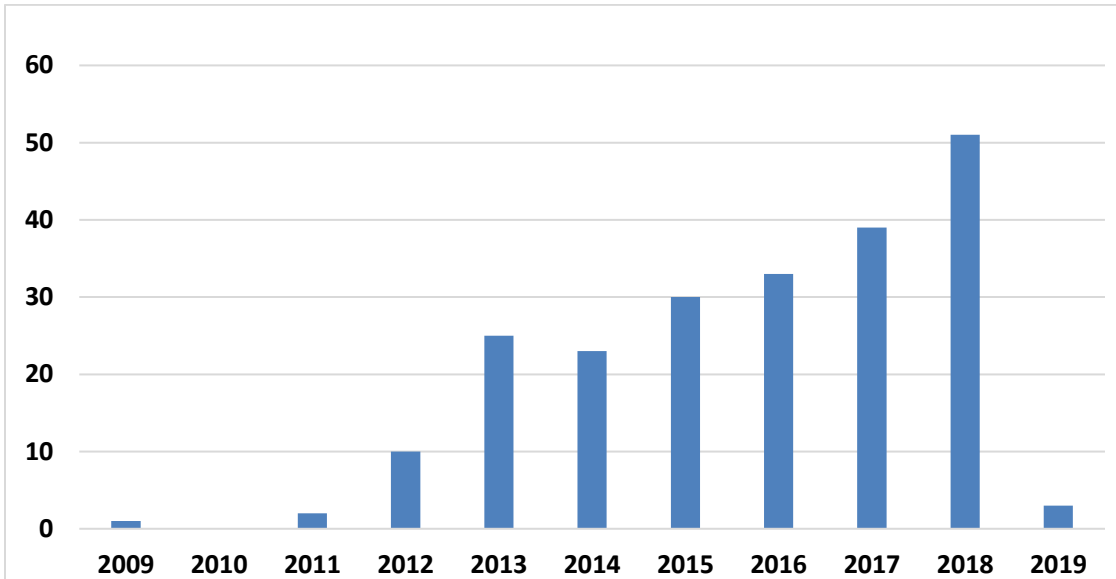
- Predictors, and Effect on Patient-Derived Outcome Measures. *Spine (Phila Pa 1976)* 2016;1–10. doi:10.1097/BRS.0000000000001552.
- 113) Passias PG, Oh C, Jalai CM, Worley N, Lafage R, Scheer JK, et al. Predictive Model for Cervical Alignment and Malalignment Following Surgical Correction of Adult Spinal Deformity. *Spine (Phila Pa 1976)* 2016;1–10. doi:10.1097/BRS.0000000000001640.
- 114) Passias PG, Soroceanu A, Yang S, Schwab FJ, Ames C, Boniello A, et al. Predictors of Revision Surgical Procedure Excluding Wound Complications in Adult Spinal Deformity and Impact on Patient-Reported Outcomes and Satisfaction: A Two-Year Follow-up. *J Bone Joint Surg Am* 2016;98:536–43. doi:10.2106/JBJS.14.01126.
- 115) Scheer JK, Hostin R, Robinson C, Schwab FJ, Lafage V, Burton DC, et al. Operative Management of Adult Spinal Deformity Results in Significant Increases in QALYs Gained Compared to Non-operative Management: Analysis of 479 patients with Minimum 2-year Follow-up. *Spine (Phila Pa 1976)* 2016. doi:10.1097/BRS.0000000000001626.
- 116) Scheer JK, Osorio JA, Smith JS, Schwab FJ, Lafage V, Hart RA, et al. Development of Validated Computer-based Preoperative Predictive Model for Proximal Junction Failure (PJF) or Clinically Significant PJK With 86% Accuracy Based on 510 ASD Patients With 2-year Follow-up. *Spine (Phila Pa 1976)* 2016;41:E1328–35. doi:10.1097/BRS.0000000000001598.
- 117) Smith JS, Klineberg E, Shaffrey CI, Lafage V, Schwab FJ, Protosaltis T, et al. Assessment of Surgical Treatment Strategies for Moderate to Severe Cervical Spinal Deformity Reveals Marked Variation in Approaches, Osteotomies and Fusion Levels. *World Neurosurg* 2016;91:228–37. doi:10.1016/j.wneu.2016.04.020.
- 118) Smith JS, Lafage V, Shaffrey CI, Schwab FJ, Lafage R, Hostin R, et al. Outcomes of Operative and Nonoperative Treatment for Adult Spinal Deformity: A Prospective, Multicenter, Propensity-Matched Cohort Assessment With Minimum 2-Year Follow-up. *Neurosurgery* 2016;78:851–61. doi:10.1227/NEU.0000000000001116.
- 119) Smith JS, Ramchandran S, Lafage V, Shaffrey CI, Ailon T, Klineberg E, et al. Prospective Multicenter Assessment of Early Complication Rates Associated With Adult Cervical Deformity Surgery in 78 Patients. *Neurosurgery* 2016;79:378–88. doi:10.1227/NEU.0000000000001129.
- 120) Smith JS, Klineberg E, Lafage V, Shaffrey CI, Schwab FJ, Lafage R, et al. Prospective multicenter assessment of perioperative and minimum 2-year postoperative complication rates associated with adult spinal deformity surgery. *J Neurosurg Spine* 2016;1–14. doi:10.3171/2015.11.SPINE151036.
- 121) Soroceanu A, Burton DC, Oren JH, Smith JS, Hostin R, Shaffrey CI, et al. Medical Complications after Adult Spinal Deformity Surgery: Incidence, Risk factors, and Clinical Impact. *Spine (Phila Pa 1976)* 2016;18:345–52. doi:10.1097/BRS.0000000000001636.
- 122) Soroceanu A, Oren JH, Smith JS, Hostin R, Shaffrey CI, Mundis GM, et al. Effect of Antifibrinolytic Therapy on Complications, Thromboembolic Events, Blood Product Utilization, and Fusion in Adult Spinal Deformity Surgery. *Spine (Phila Pa 1976)* 2016;41:E879-86. doi:10.1097/BRS.0000000000001454.
- 123) Than KD, Park P, Fu K, Nguyen S, Wang MY, Chou D, et al. Clinical and radiographic parameters associated with best versus worst clinical outcomes in minimally invasive spinal deformity surgery. *J Neurosurg Spine* 2016;25:21–5. doi:10.3171/2015.12.SPINE15999.
- 124) Theologis AA, Ailon T, Scheer JK, Smith JS, Shaffrey CI, Bess S, et al. Impact of preoperative depression on 2-year clinical outcomes following adult spinal deformity surgery: the importance of risk stratification based on type of psychological distress. *J Neurosurg Spine* 2016;1–9. doi:10.3171/2016.2.SPINE15980.
- 125) Bakhsheshian J, Scheer JK, Gum JL, Horner L, Hostin R, Lafage V, et al. Comparison of Structural Disease Burden to Health-related Quality of Life Scores in 264 Adult Spinal Deformity Patients

- With 2-Year Follow-up: Novel Insights into Drivers of Disability. *Clin Spine Surg* 2017;30:E124–31. doi:10.1097/BSD.0000000000000470.
- 126) Bakhsheshian J, Scheer JK, Gum JL, Hostin R, Lafage V, Bess S, et al. Impact of poor mental health in adult spinal deformity patients with poor physical function: a retrospective analysis with a 2-year follow-up. *J Neurosurg Spine* 2017;26:116–24. doi:10.3171/2016.5.SPINE151428.
- 127) Buckland AJ, Puvanesarajah V, Vigdorichik J, Schwarzkopf R, Jain A, Klineberg EO, et al. Dislocation of a primary total hip arthroplasty is more common in patients with a lumbar spinal fusion. *Bone Joint J* 2017;99–B:585–91. doi:10.1302/0301-620X.99B5.BJJ-2016-0657.R1.
- 128) Buckland AJ, Poorman G, Freitag R, Jalai C, Klineberg E, Kelly M, et al. National Administrative Databases in Adult Spinal Deformity Surgery - A Cautionary Tale. *Spine (Phila Pa 1976)* 2017. doi:10.1097/BRS.0000000000002064.
- 129) Bumpass DB, Lenke LG, Gum JL, Shaffrey CI, Smith JS, Ames CP, et al. Male sex may not be associated with worse outcomes in primary all-posterior adult spinal deformity surgery: a multicenter analysis. *Neurosurg Focus* 2017;43:E9. doi:10.3171/2017.9.FOCUS17475.
- 130) Diebo BG, Gammal I, Ha Y, Yoon SH, Chang JW, Kim B, et al. Role of Ethnicity in Alignment Compensation: Propensity Matched Analysis of Differential Compensatory Mechanism Recruitment Patterns for Sagittal Malalignment in 288 ASD Patients From Japan, Korea, and United States. *Spine (Phila Pa 1976)* 2017;42:E234–40. doi:10.1097/BRS.0000000000001744.
- 131) Eastlack RK, Mundis GM, Wang M, Mummaneni P V, Uribe J, Okonkwo D, et al. Is There a Patient Profile That Characterizes a Patient With Adult Spinal Deformity as a Candidate for Minimally Invasive Surgery? *Glob Spine J* 2017;7:703–8. doi:10.1177/2192568217716151.
- 132) Ferrero E, Liabaud B, Henry JK, Ames CP, Kebaish K, Mundis GM, et al. Sagittal alignment and complications following lumbar 3-column osteotomy: does the level of resection matter? *J Neurosurg Spine* 2017;27:560–9. doi:10.3171/2017.3.SPINE16357.
- 133) Gomez JA, Lafage V, Scuibba DM, Bess S, Mundis GM, Liabaud B, et al. Adult Scoliosis Deformity Surgery: Comparison of Outcomes Between One Versus Two Attending Surgeons. *Spine (Phila Pa 1976)* 2017;42:992–8. doi:10.1097/BRS.0000000000002071.
- 134) Gum JL, Carreon LY, Kelly MP, Hostin R, Robinson C, Burton DC, et al. Cell Saver for Adult Spinal Deformity Surgery Reduces Cost. *Spine Deform* 2017;5:272–6. doi:10.1016/j.jspd.2017.01.005.
- 135) Gum JL, Hostin R, Robinson C, Kelly MP, Carreon LY, Polly DW, et al. Impact of cost valuation on cost-effectiveness in adult spine deformity surgery. *Spine J* 2017;17:96–101. doi:10.1016/j.spinee.2016.08.020.
- 136) Hamilton DK, Buza JA, Passias P, Jalai C, Kim HJ, Ailon T, et al. The Fate of Patients with Adult Spinal Deformity Incurring Rod Fracture After Thoracolumbar Fusion. *World Neurosurg* 2017;106:905–11. doi:10.1016/j.wneu.2017.07.061.
- 137) Hamilton DK, Kong C, Hiratzka J, Contag AG, Ailon T, Line B, et al. Patient Satisfaction After Adult Spinal Deformity Surgery Does Not Strongly Correlate With Health-Related Quality of Life Scores, Radiographic Parameters, or Occurrence of Complications. *Spine (Phila Pa 1976)* 2017;42:764–9. doi:10.1097/BRS.0000000000001921.
- 138) Jain A, Hassanzadeh H, Puvanesarajah V, Klineberg EO, Sciubba DM, Kelly MP, et al. Incidence of perioperative medical complications and mortality among elderly patients undergoing surgery for spinal deformity: analysis of 3519 patients. *J Neurosurg Spine* 2017;27:534–9. doi:10.3171/2017.3.SPINE161011.
- 139) Jain A, Kebaish KM, Sciubba DM, Hassanzadeh H, Scheer JK, Neuman BJ, et al. Early Patient-Reported Outcomes Predict 3-Year Outcomes in Operatively Treated Patients with Adult Spinal Deformity. *World Neurosurg* 2017. doi:10.1016/j.wneu.2017.03.003.
- 140) Kim HJ, Iyer S, Zebala LP, Kelly MP, Sciubba D, Protopsaltis TS, et al. Perioperative Neurologic Complications in Adult Spinal Deformity Surgery: Incidence and Risk Factors in 564 Patients. *Spine*

- (Phila Pa 1976) 2017;42:420–7. doi:10.1097/BRS.0000000000001774.
- 141) Lafage R, Bess S, Glassman S, Ames C, Burton D, Hart R, et al. Virtual Modeling of Postoperative Alignment After Adult Spinal Deformity Surgery Helps Predict Associations Between Compensatory Spinopelvic Alignment Changes, Overcorrection, and Proximal Junctional Kyphosis. *Spine (Phila Pa 1976)* 2017;42:E1119–25. doi:10.1097/BRS.0000000000002116.
- 142) Lafage R, Bess S, Glassman S, Ames C, Burton D, Hart R, et al. Virtual Modeling of Postoperative Alignment After Adult Spinal Deformity Surgery Helps Predict Associations Between Compensatory Spinopelvic Alignment Changes, Overcorrection, and Proximal Junctional Kyphosis. *Spine (Phila Pa 1976)* 2017;42:E1119–25. doi:10.1097/BRS.0000000000002116.
- 143) Lafage R, Line BG, Gupta S, Liabaud B, Schwab FJ, Smith JS, et al. Orientation of the Upper-most Instrumented Segment Influences Proximal Junctional Disease Following Adult Spinal Deformity Surgery. *Spine (Phila Pa 1976)* 2017;42:1570–7. doi:10.1097/BRS.0000000000002191.
- 144) Lafage R, Schwab FJ, Glassman S, Bess S, Harris B, Sheer J, et al. Age-Adjusted Alignment Goals Have the Potential to Reduce PJK. *Spine (Phila Pa 1976)* 2017;42:1275–82. doi:10.1097/BRS.0000000000002146.
- 145) Miller EK, Neuman BJ, Jain A, Daniels AH, Ailon T, Sciubba DM, et al. An assessment of frailty as a tool for risk stratification in adult spinal deformity surgery. *Neurosurg Focus* 2017;43:E3. doi:10.3171/2017.10.FOCUS17472.
- 146) Mundis GM, Turner JD, Deverin V, Uribe JS, Nunley P, Mummaneni P, et al. A Critical Analysis of Sagittal Plane Deformity Correction With Minimally Invasive Adult Spinal Deformity Surgery: A 2-Year Follow-Up Study. *Spine Deform* 2017;5:265–71. doi:10.1016/j.jspd.2017.01.010.
- 147) Mundis GM, Turner JD, Kabirian N, Pawelek J, Eastlack RK, Uribe J, et al. Anterior Column Realignment has Similar Results to Pedicle Subtraction Osteotomy in Treating Adults with Sagittal Plane Deformity. *World Neurosurg* 2017;105:249–56. doi:10.1016/j.wneu.2017.05.122.
- 148) Nunley PD, Mundis GM, Fessler RG, Park P, Zavatsky JM, Uribe JS, et al. Impact of case type, length of stay, institution type, and comorbidities on Medicare diagnosis-related group reimbursement for adult spinal deformity surgery. *Neurosurg Focus* 2017;43:E11. doi:10.3171/2017.7.FOCUS17278.
- 149) Oh T, Scheer JK, Smith JS, Hostin R, Robinson C, Gum JL, et al. Potential of predictive computer models for preoperative patient selection to enhance overall quality-adjusted life years gained at 2-year follow-up: a simulation in 234 patients with adult spinal deformity. *Neurosurg Focus* 2017;43:E2. doi:10.3171/2017.9.FOCUS17494.
- 150) Passias PG, Horn SR, Jalai CM, Poorman G, Bono OJ, Ramchandran S, et al. Comparative analysis of perioperative complications between a multicenter prospective cervical deformity database and the Nationwide Inpatient Sample database. *Spine J* 2017;17:1633–40. doi:10.1016/j.spinee.2017.05.018.
- 151) Passias PG, Poorman GW, Jalai CM, Line B, Diebo B, Park P, et al. Outcomes of open staged corrective surgery in the setting of adult spinal deformity. *Spine J* 2017. doi:10.1016/j.spinee.2017.03.012.
- 152) Poorman GW, Passias PG, Buckland AJ, Jalai CM, Kelly M, Sciubba DM, et al. Comparative Analysis of Perioperative Outcomes Using Nationally Derived Hospital Discharge Data Relative to a Prospective Multicenter Surgical Database of Adult Spinal Deformity Surgery. *Spine (Phila Pa 1976)* 2017;42:1165–71. doi:10.1097/BRS.0000000000002002.
- 153) Poorman GW, Passias PG, Horn SR, Frangella NJ, Daniels AH, Hamilton DK, et al. Despite worse baseline status depressed patients achieved outcomes similar to those in nondepressed patients after surgery for cervical deformity. *Neurosurg Focus* 2017;43:E10. doi:10.3171/2017.8.FOCUS17486.
- 154) Protopsaltis TS, Lafage R, Vira S, Sciubba D, Soroceanu A, Hamilton K, et al. Novel Angular

- Measures of Cervical Deformity Account for Upper Cervical Compensation and Sagittal Alignment. *Clin Spine Surg* 2017;30:E959–67. doi:10.1097/BSD.0000000000000554.
- 155) Protopsaltis T, Bronsard N, Soroceanu A, Henry JK, Lafage R, Smith J, et al. Cervical sagittal deformity develops after PJK in adult thoracolumbar deformity correction: radiographic analysis utilizing a novel global sagittal angular parameter, the CTPA. *Eur Spine J* 2017;26:1111–20. doi:10.1007/s00586-016-4653-7.
- 156) Scheer JK, Keefe M, Lafage V, Kelly MP, Bess S, Burton DC, et al. Importance of patient-reported individualized goals when assessing outcomes for adult spinal deformity (ASD): initial experience with a Patient Generated Index (PGI). *Spine J* 2017. doi:10.1016/j.spinee.2017.04.013.
- 157) Scheer JK, Smith JS, Schwab FJ, Lafage V, Shaffrey CI, Bess S, et al. Development of a preoperative predictive model for major complications following adult spinal deformity surgery. *J Neurosurg Spine* 2017;26:736–43. doi:10.3171/2016.10.SPINE16197.
- 158) Smith JS, Line B, Bess S, Shaffrey CI, Kim HJ, Mundis G, et al. The Health Impact of Adult Cervical Deformity in Patients Presenting for Surgical Treatment: Comparison to United States Population Norms and Chronic Disease States Based on the EuroQuol-5 Dimensions Questionnaire. *Neurosurgery* 2017;80:716–25. doi:10.1093/neuros/nyx028.
- 159) Smith JS, Shaffrey CI, Klineberg E, Lafage V, Schwab FJ, Lafage R, et al. Complication rates associated with 3-column osteotomy in 82 adult spinal deformity patients: retrospective review of a prospectively collected multicenter consecutive series with 2-year follow-up. *J Neurosurg Spine* 2017;1–14. doi:10.3171/2016.10.SPINE16849.
- 160) Smith JS, Shaffrey CI, Lafage R, Lafage V, Schwab FJ, Kim HJ, et al. Three-column osteotomy for correction of cervical and cervicothoracic deformities: alignment changes and early complications in a multicenter prospective series of 23 patients. *Eur Spine J* 2017. doi:10.1007/s00586-017-5071-1.
- 161) Theologis AA, Mundis GM, Nguyen S, Okonkwo DO, Mummaneni P V, Smith JS, et al. Utility of multilevel lateral interbody fusion of the thoracolumbar coronal curve apex in adult deformity surgery in combination with open posterior instrumentation and L5-S1 interbody fusion: a case-matched evaluation of 32 patients. *J Neurosurg Spine* 2017;26:208–19. doi:10.3171/2016.8.SPINE151543.
- 162) Theologis AA, Safaee M, Scheer JK, Lafage V, Hostin R, Hart RA, et al. Magnitude, Location, and Factors Related to Regional and Global Sagittal Alignment Change in Long Adult Deformity Constructs: Report of 183 Patients With 2-Year Follow-up. *Clin Spine Surg* 2017. doi:10.1097/BSD.0000000000000503.
- 163) Uribe JS, Beckman J, Mummaneni P V, Okonkwo D, Nunley P, Wang MY, et al. Does MIS Surgery Allow for Shorter Constructs in the Surgical Treatment of Adult Spinal Deformity? *Neurosurgery* 2017;80:489–97. doi:10.1093/neuros/nyw072.

Publications per year



Publications per Journal

